

Embolotherapy in Primary Lung and Mediastinal Tumors

Institute for Image Guided Therapy

Shinichi Hori MD

Atsushi Hori MD

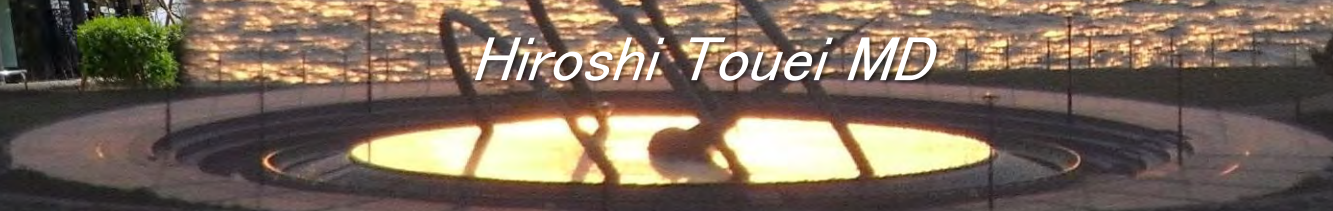Norifumi Kennoki, MD

Tatsuya Nakamura MD

Keishi Fujiwara MD

Shouta Ueda MD

Hiroshi Touei MD



Disclosure

Medical adviser for Merit Medical Systems

Trend of Embolotherapy

1980

2020

Hemoptysis

Uterine Fibroid

Breast tumors

HCC embolization

Prostatic Hypertrophy

Trans-
Arterial
Chemo-
Embolization

Angiomyolipoma

Lung tumors

Obesity

Splenomegaly

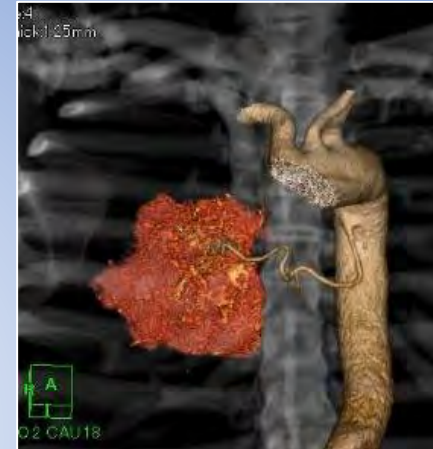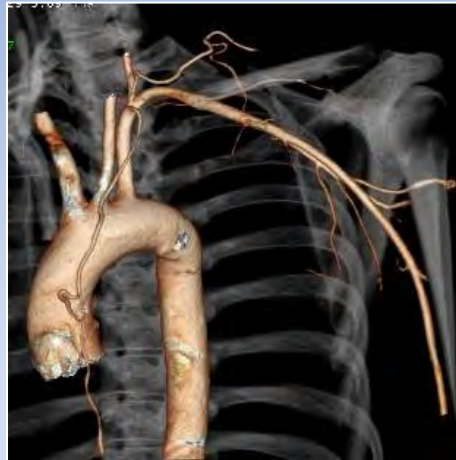
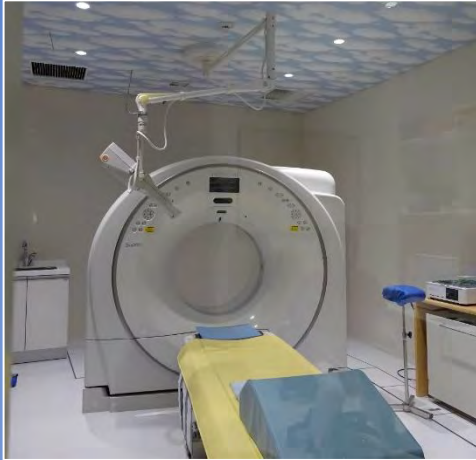Hemorrhoid

Liver Mets

etc.

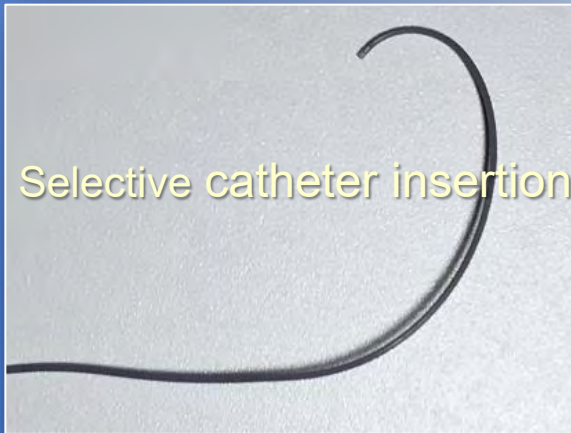
The background of embolotherapy

Diagnostic advancement

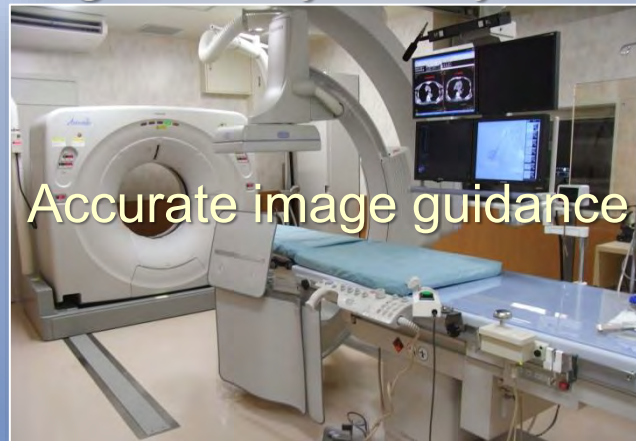

Medical Device advancement

Microcatheter



Angio-CT hybrid system



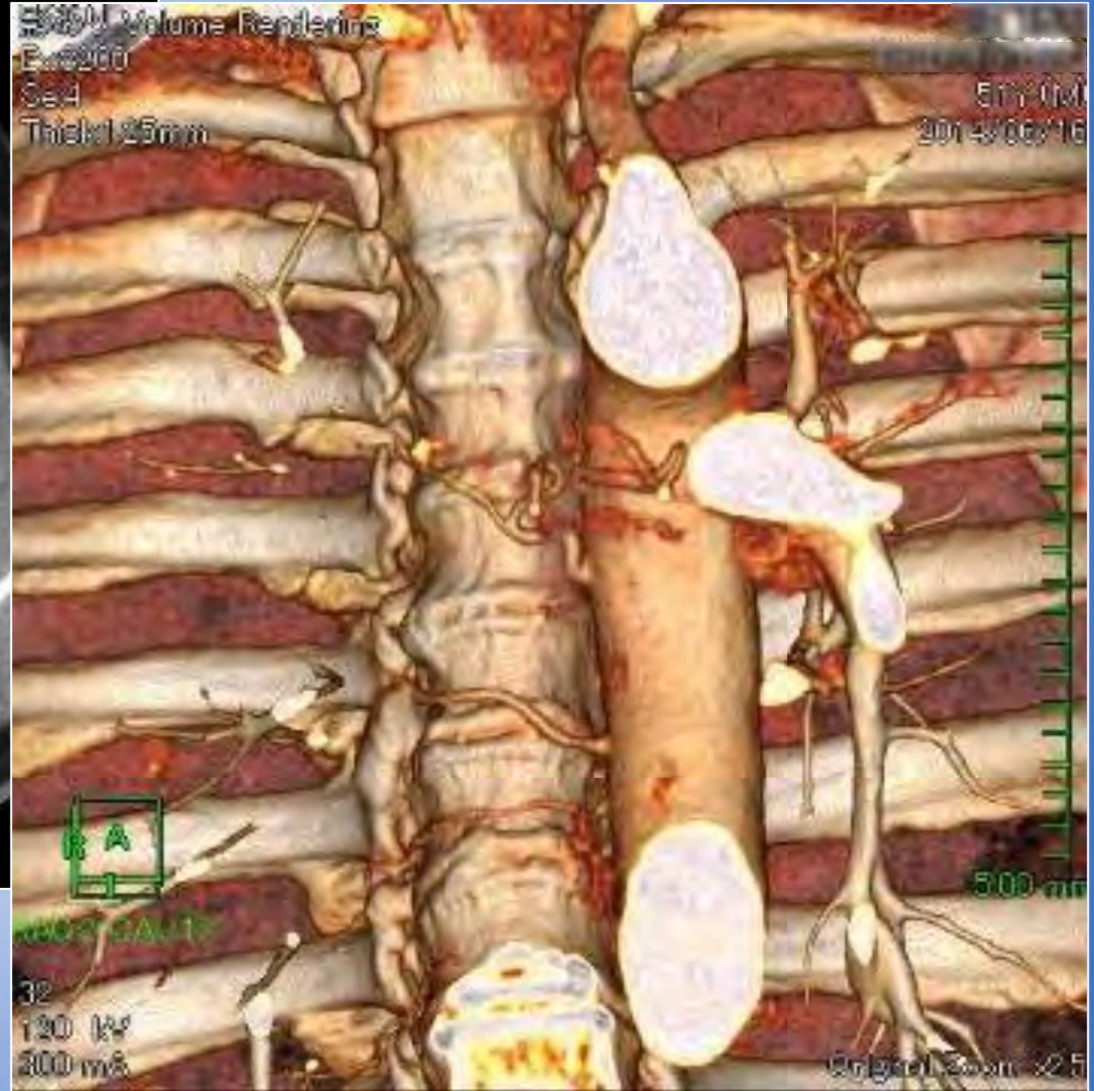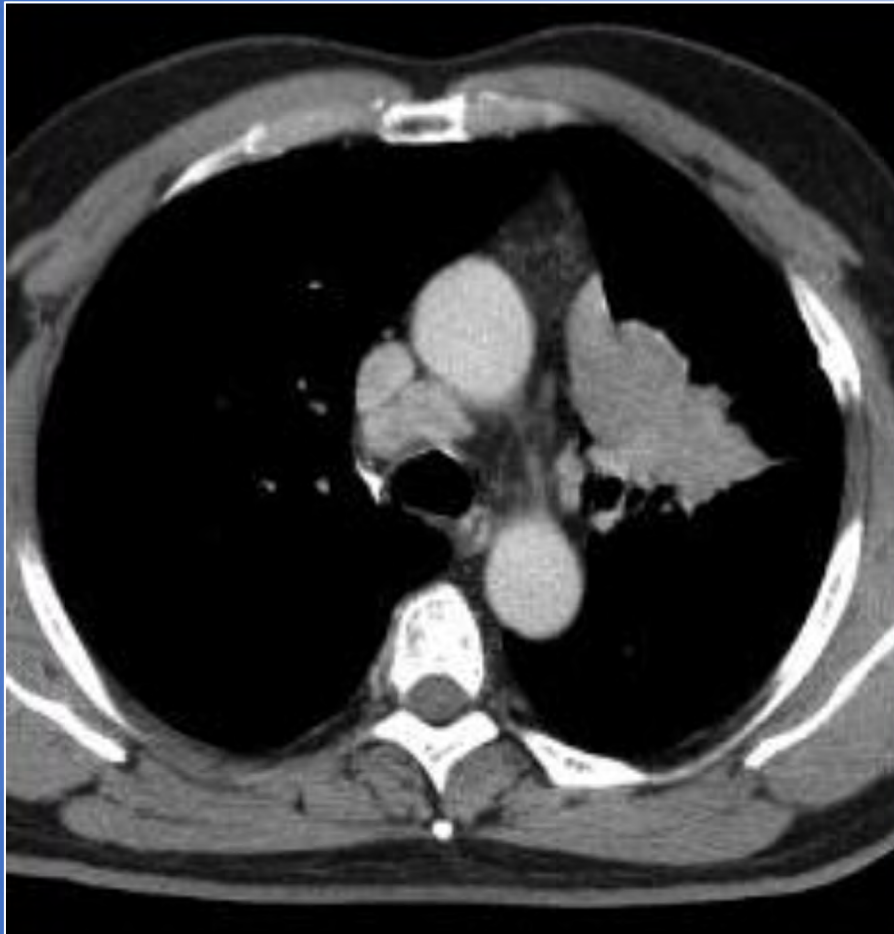
Spherical embolic material

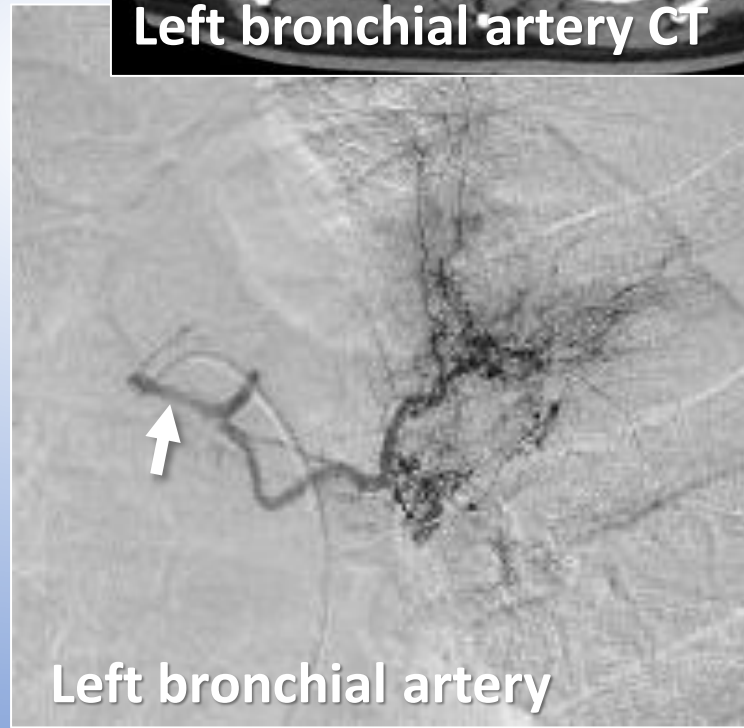
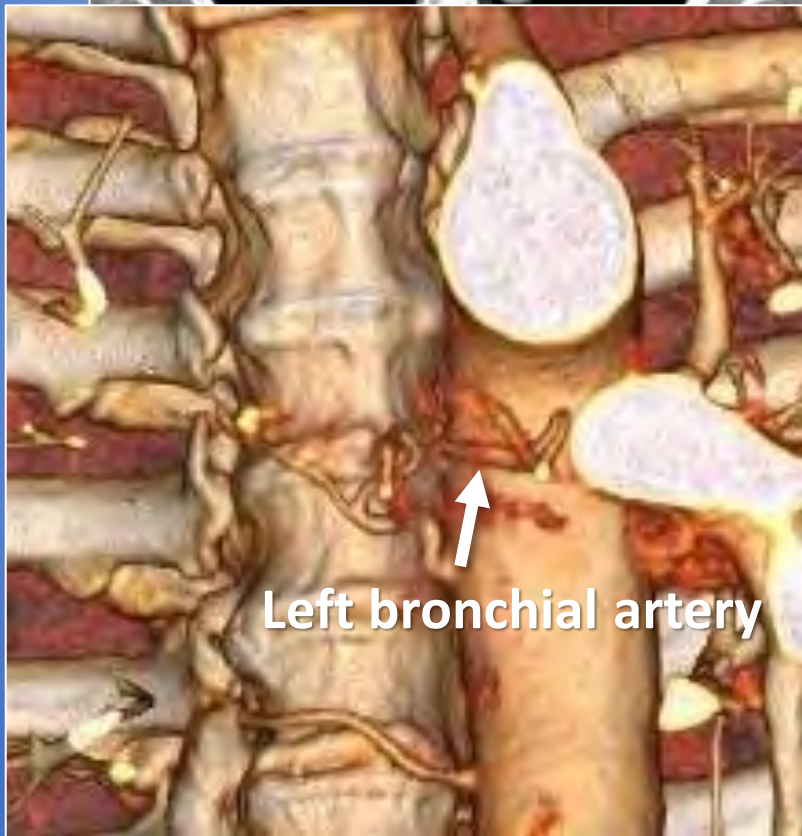
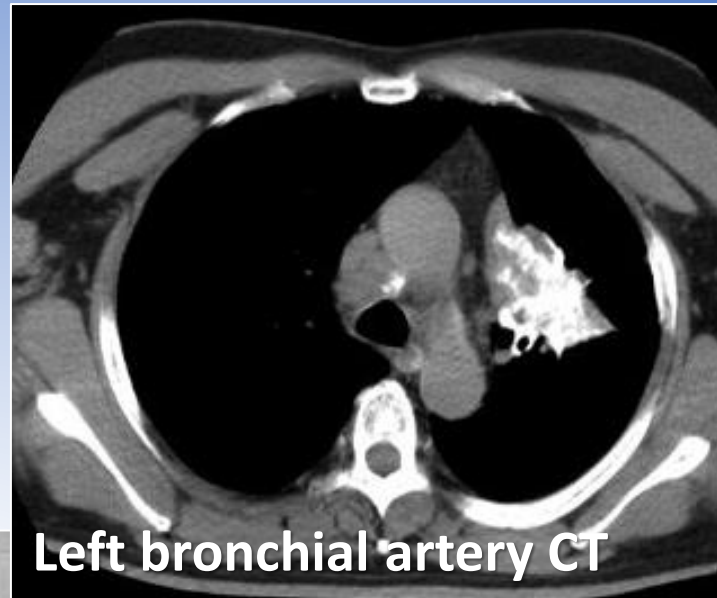
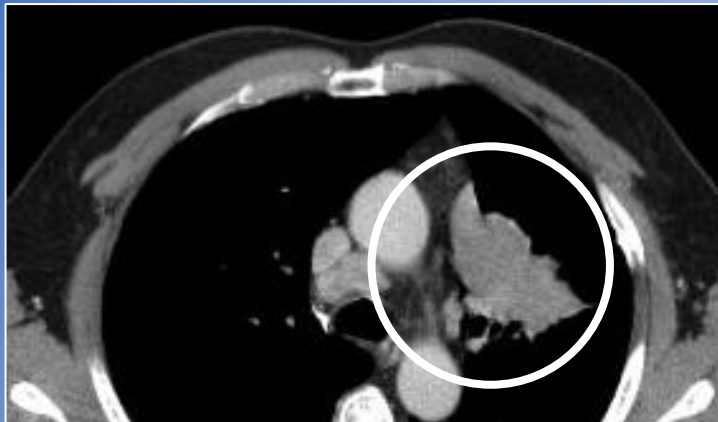


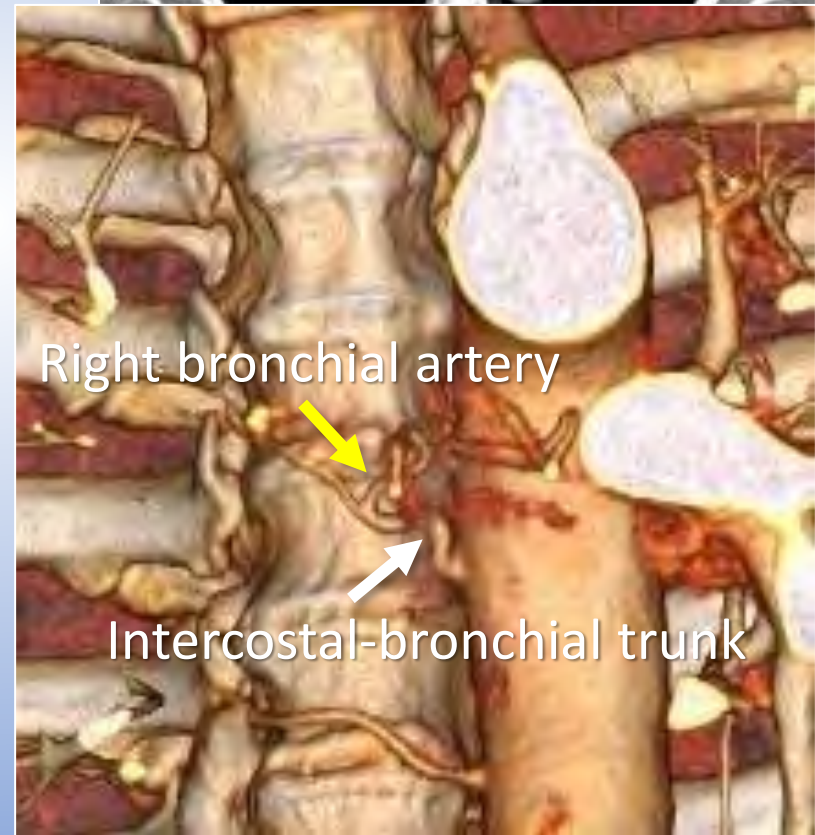
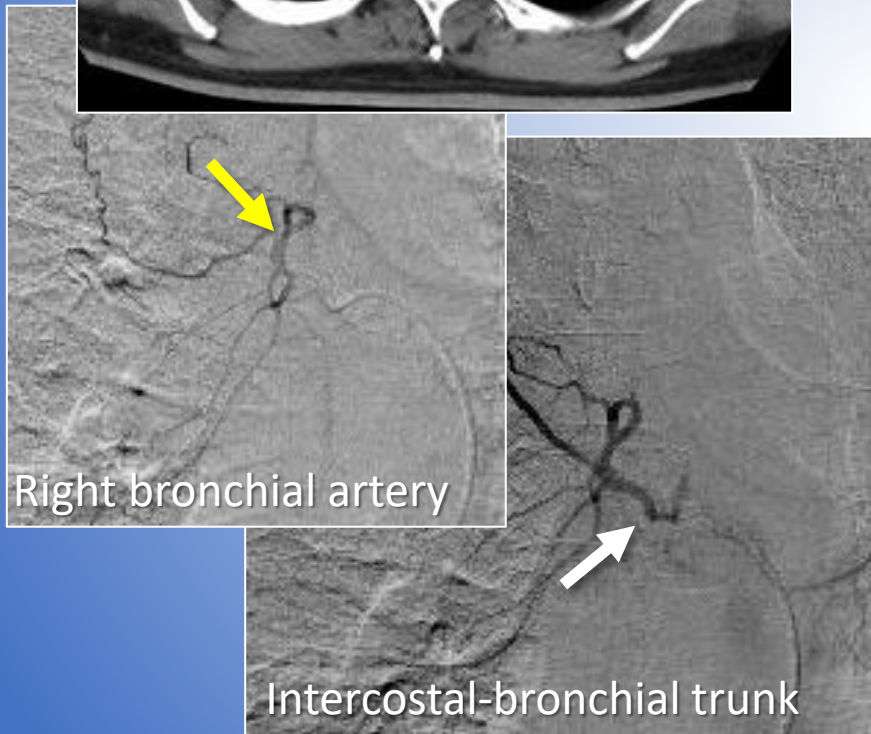
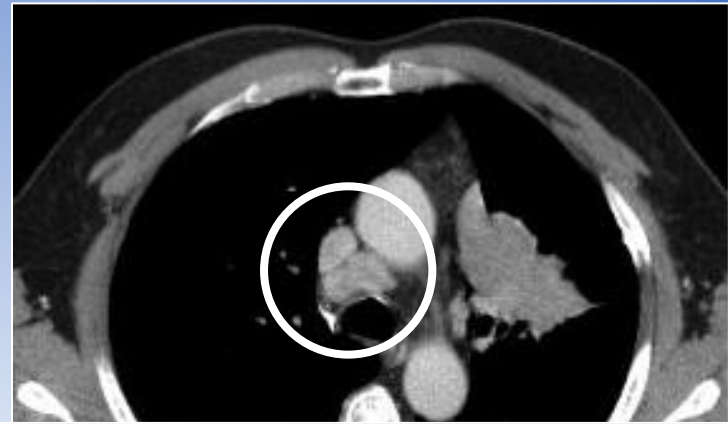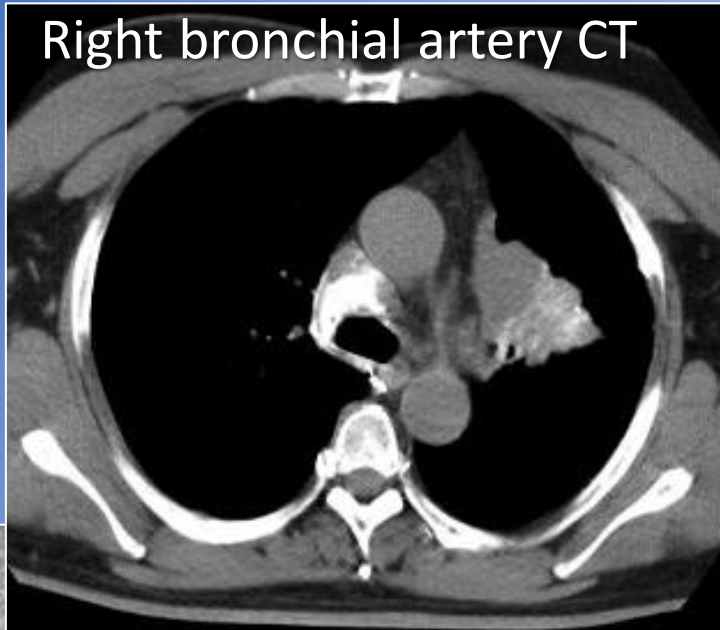


Primary Lung Cancer

Anatomy and Approaches

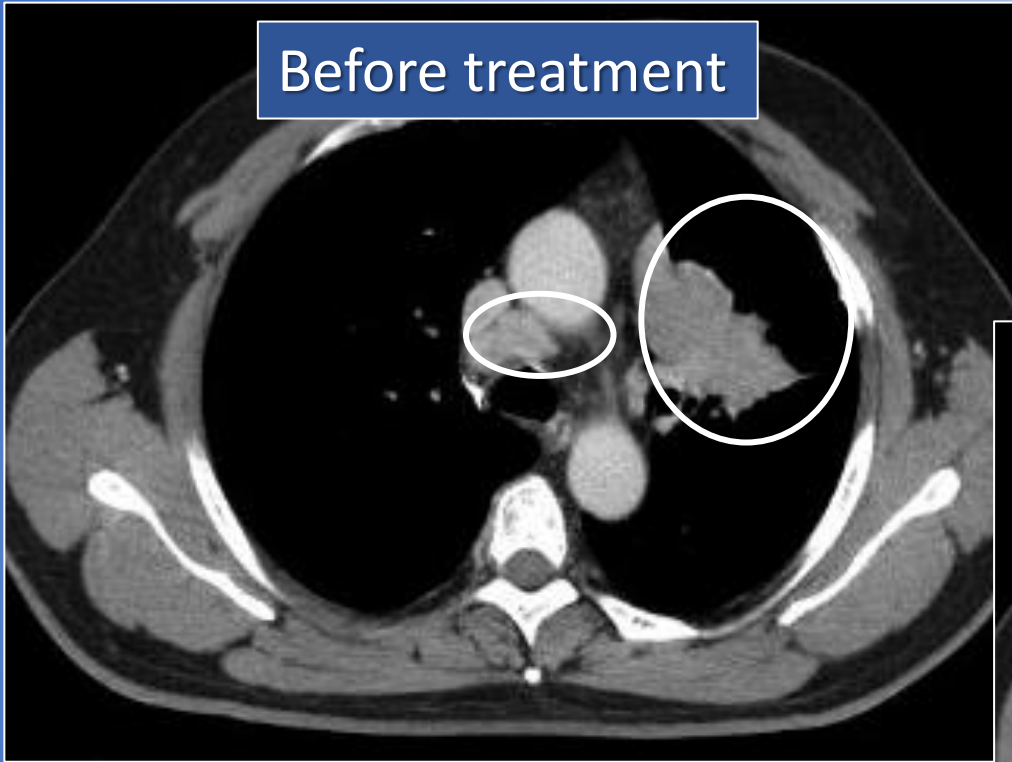




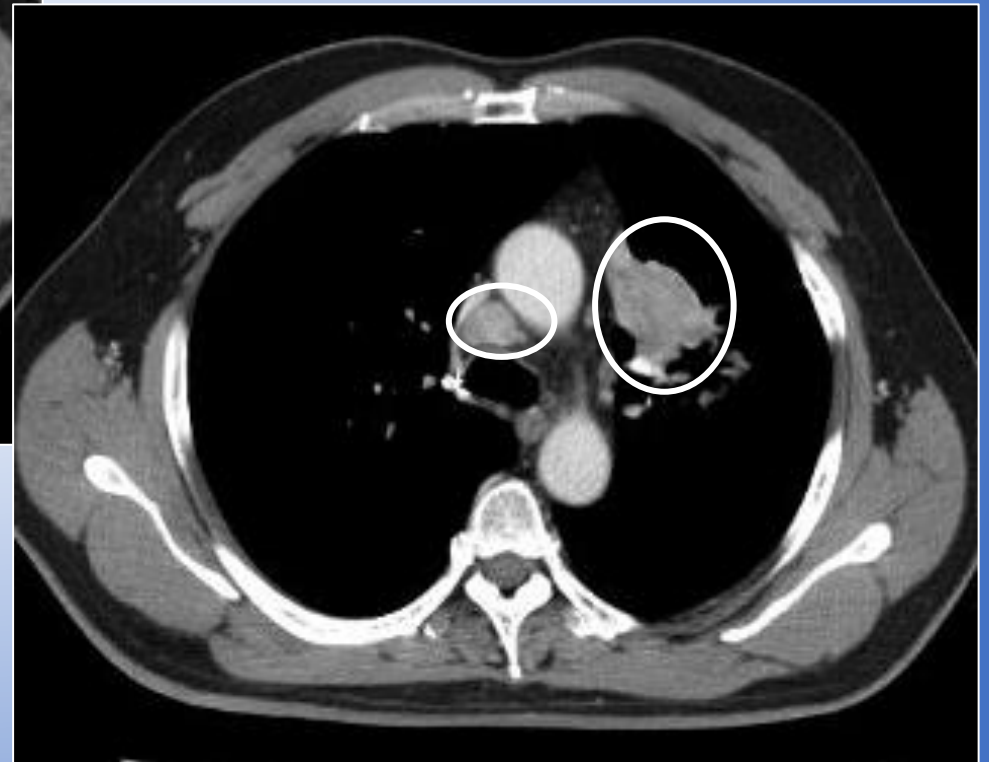


Non-Small Cell Lung Cancer 51 y/o male

Before treatment



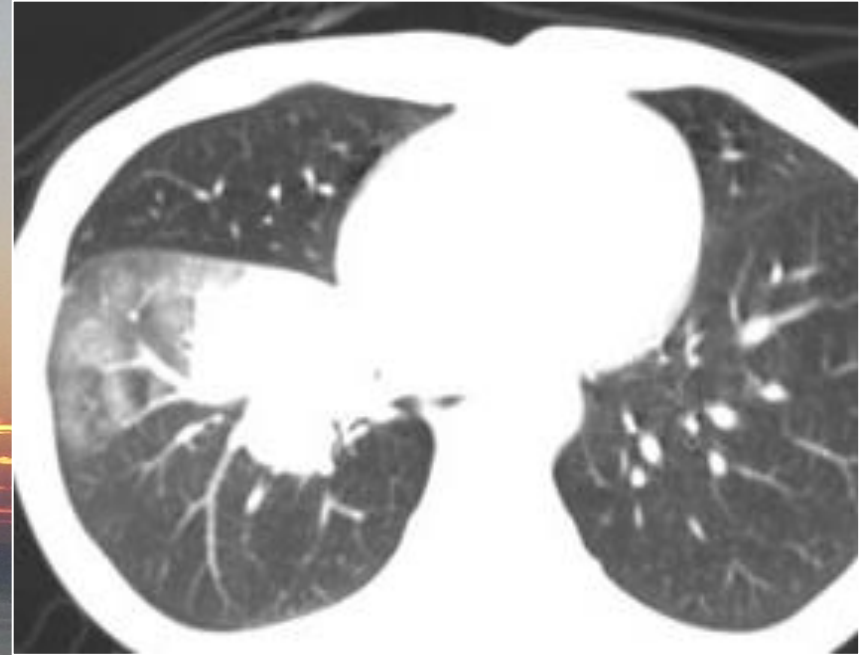
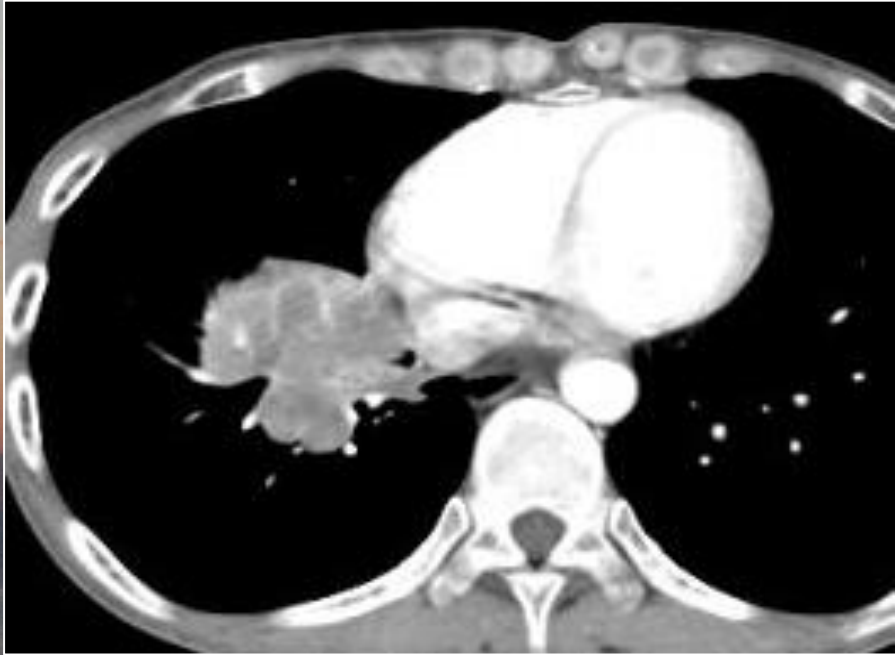2 months after treatment



Infusion: CDDP;20mg + DTX;20mg + 5-FU;250mg + Bevacizumb;100mg

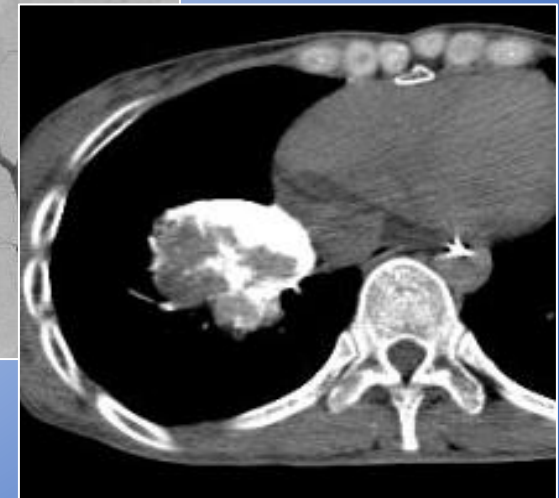
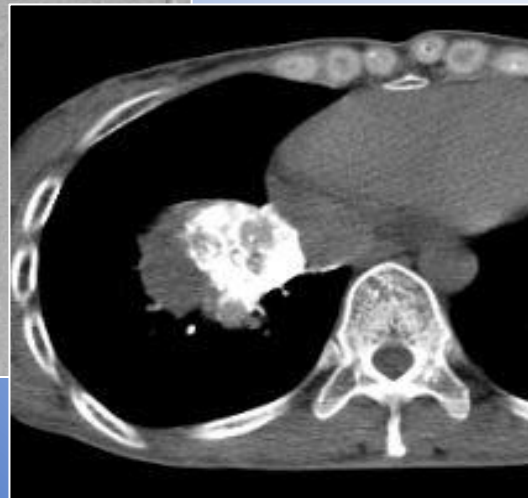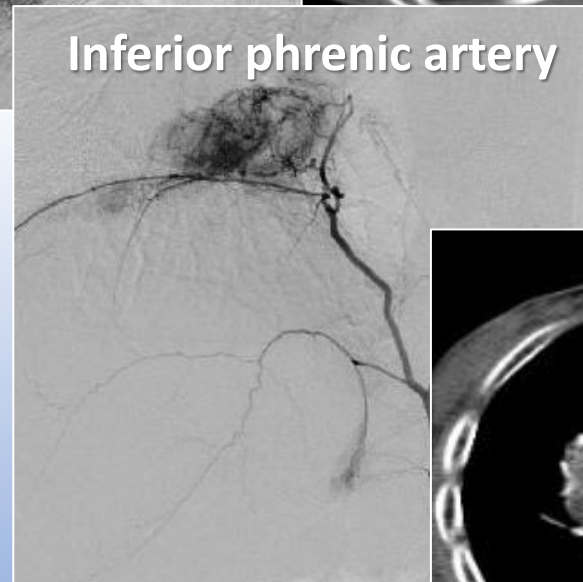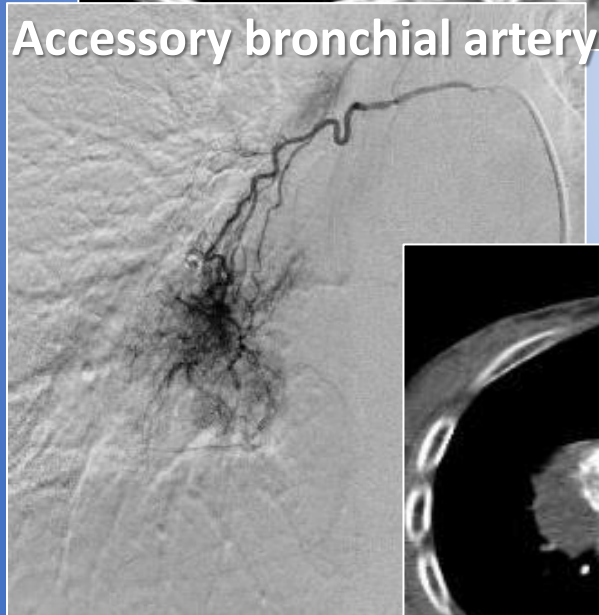
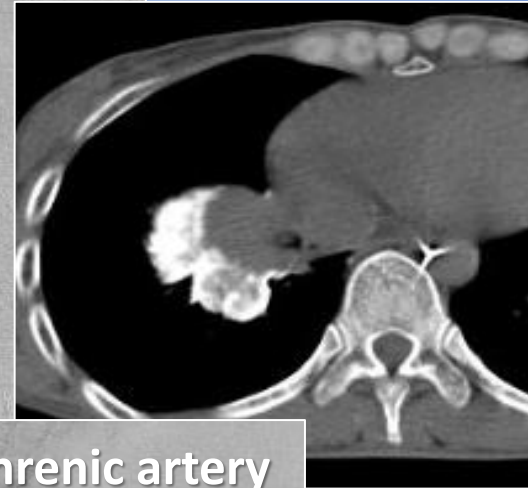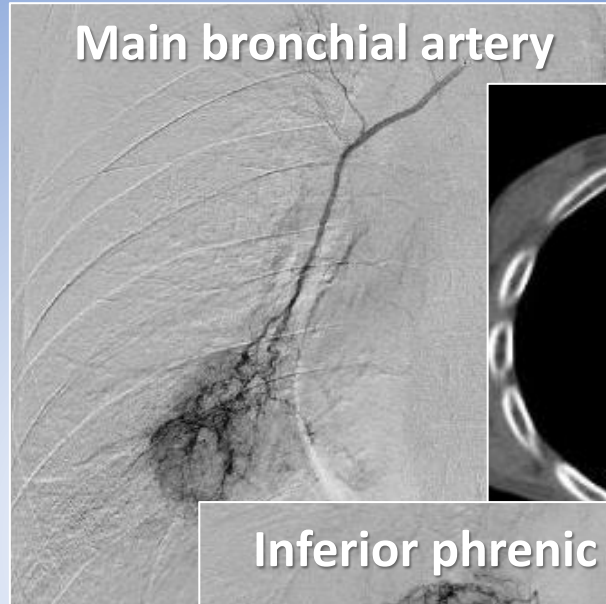
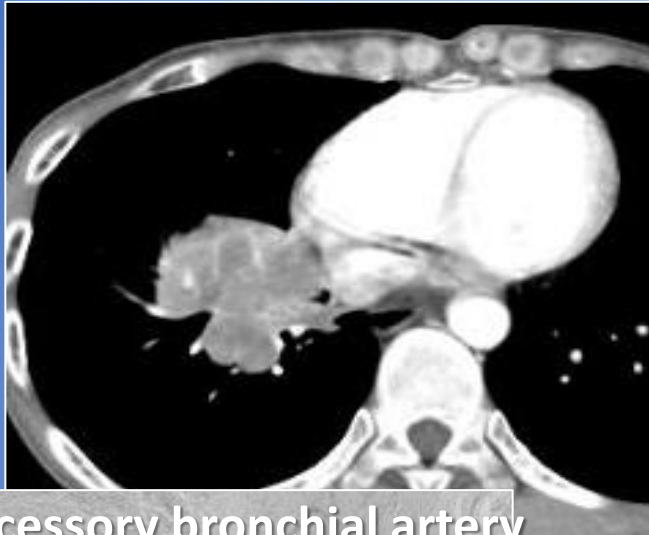Embolization: Drug Loaded HepaSphere (DTX;20mg + HS(50-100);25mg); 3.5mg

Non-small cell lung cancer, 43 y/o female



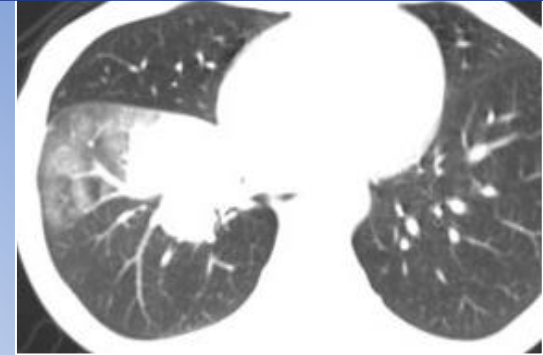
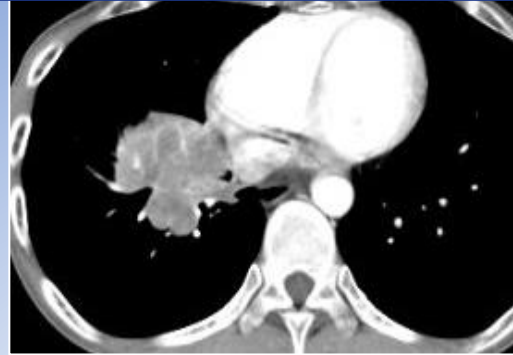Symptoms: severe cough, hemoptysis and fever

Non-small cell lung cancer, 43 y/o female



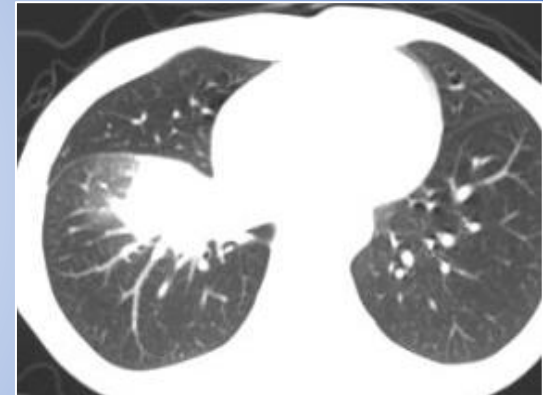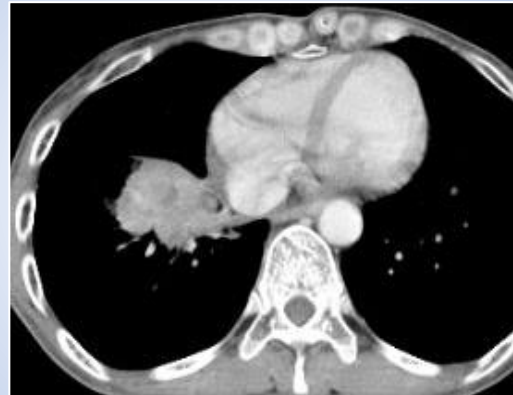Non-small cell lung cancer, 43 y/o female

CDDP:20mg, 5-FU;500mg
HepaSphere(50-100);6.0mg

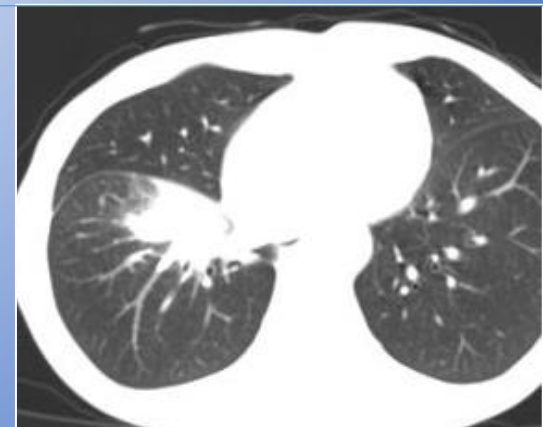
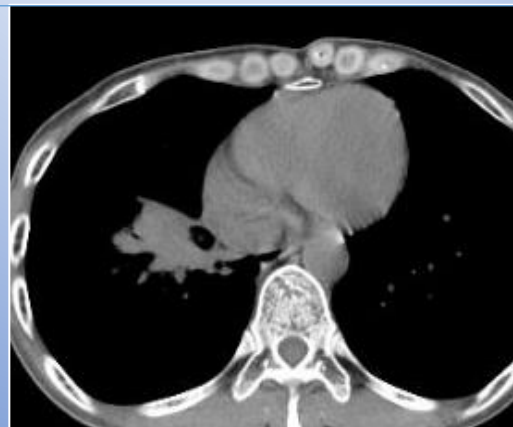
Two Months after treatment

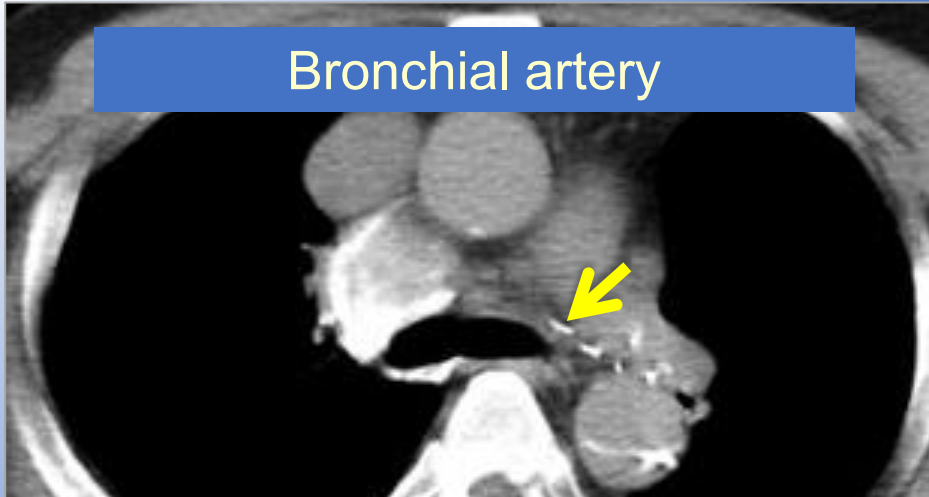
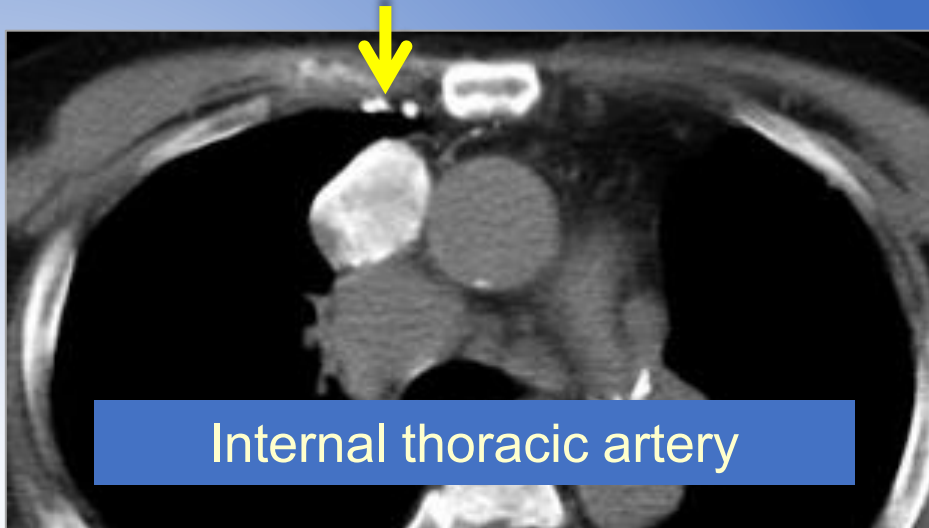
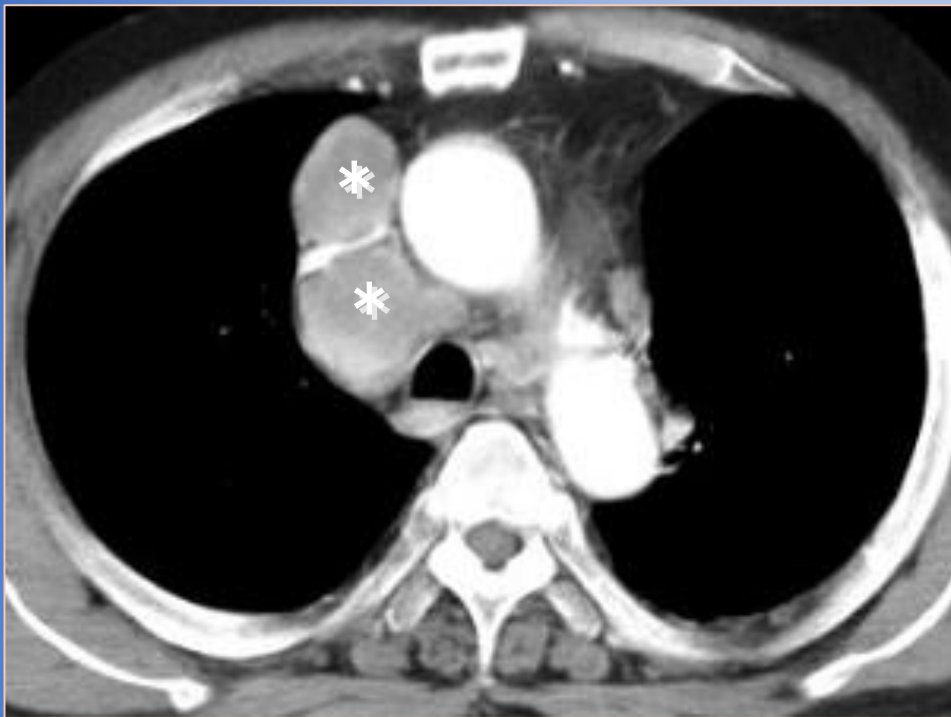
CDDP:20mg, DOC;20mg
HepaSphere(50-100);4.0mg



Three Months after treatment



Non-small cell lung cancer invading mediastinum, 63 y/o male

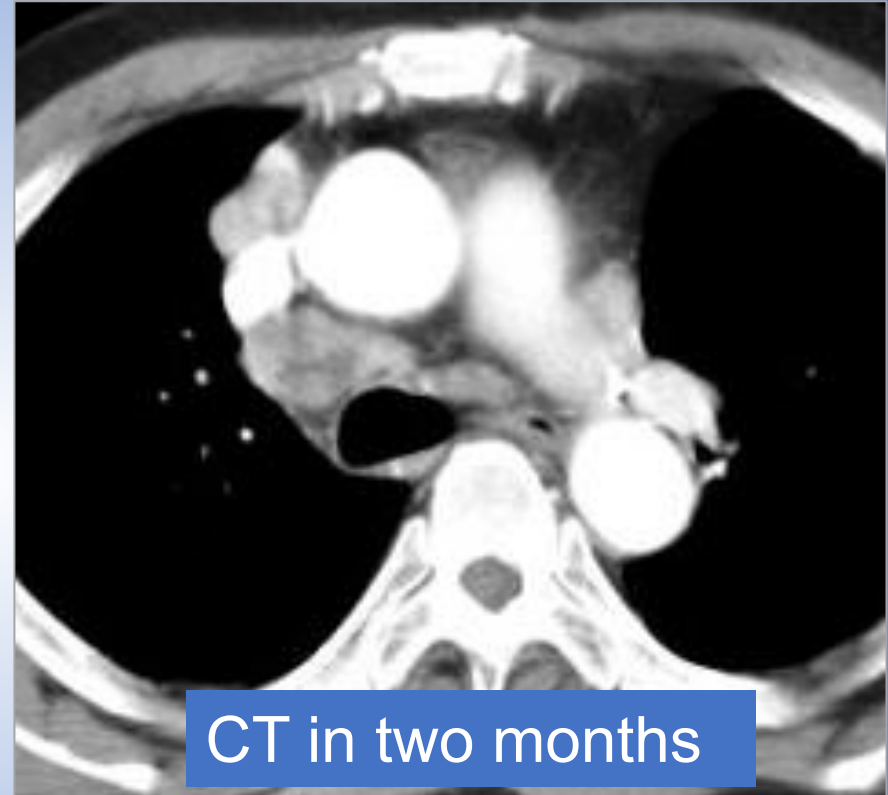
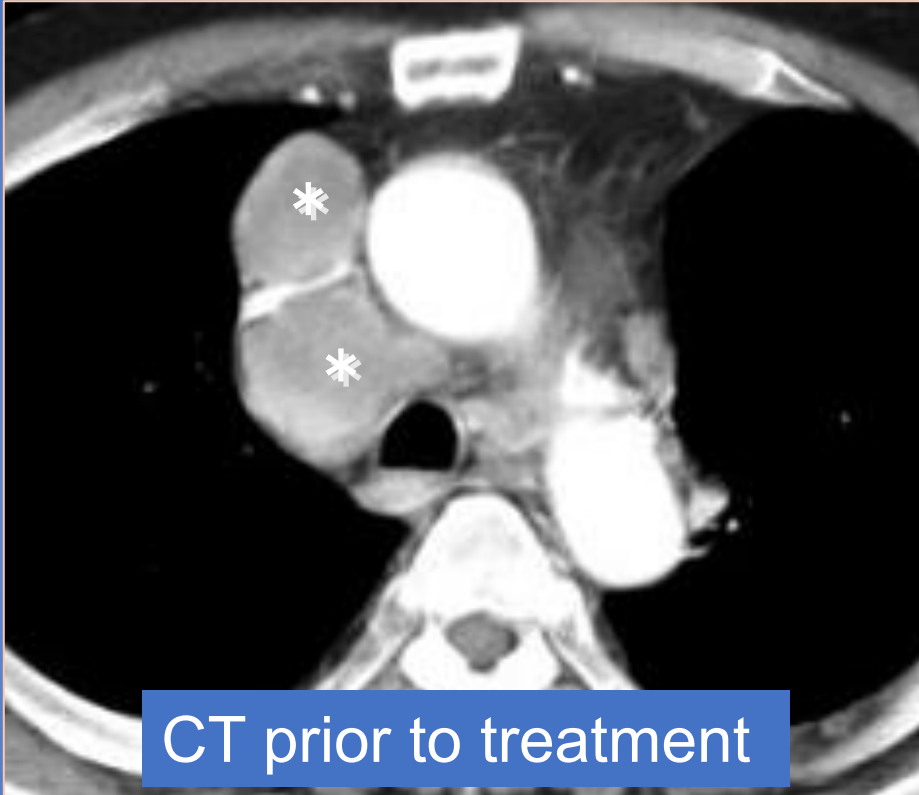


Symptoms: Respiratory distress and superior vena cava syndrome

Infusion: CDDP;30mg, 5-FU;500mg

Embolization; HepaSphere: 100-150 20mg

Non-small cell lung cancer invading mediastinum, 63 y/o male



Symptoms: Respiratory distress and superior vena cava syndrome

Markedly improved

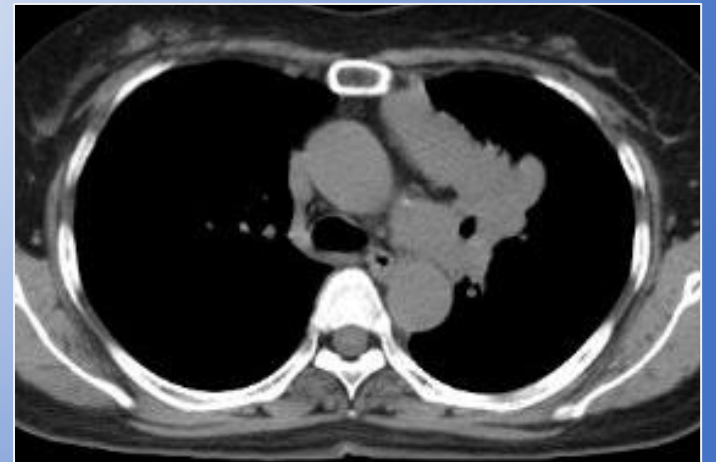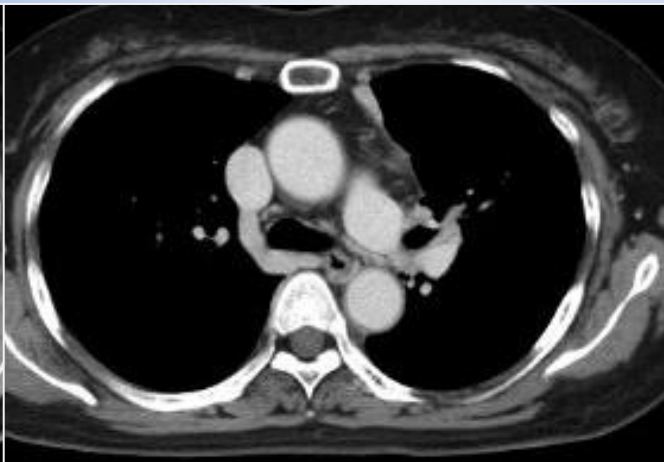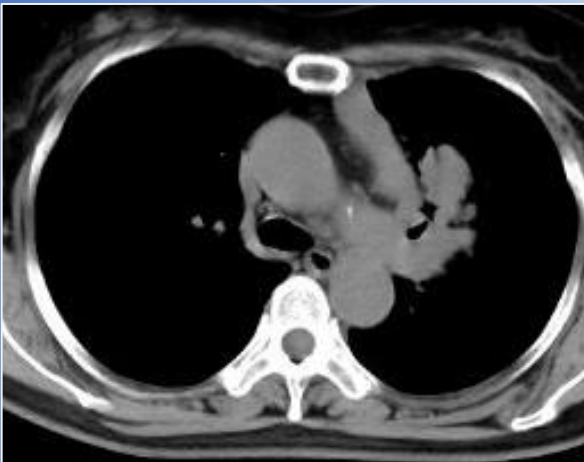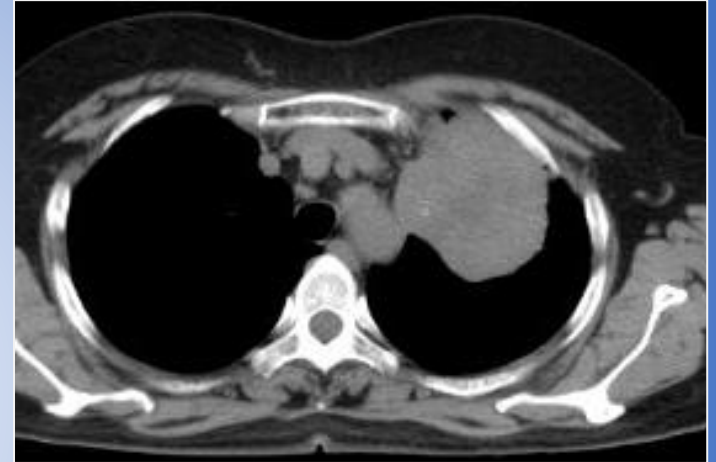
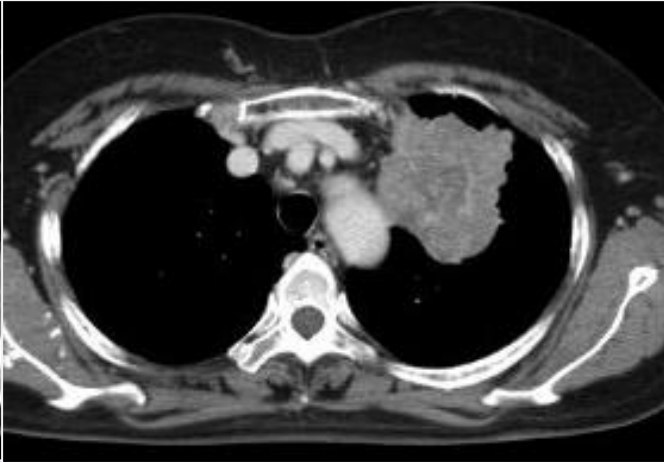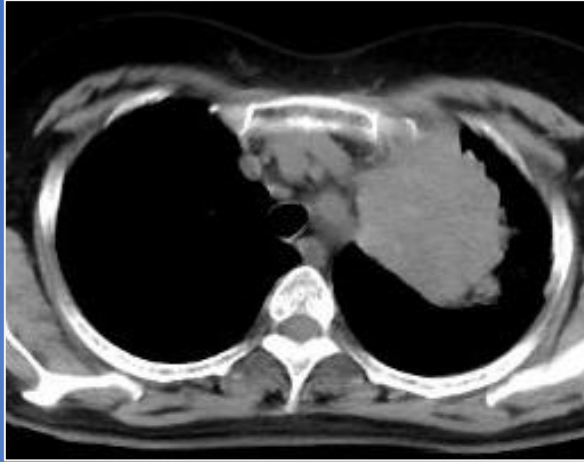
Non-Small Cell Lung Cancer (Adenocarcinoma) 70 y/o female

Afatinib: for 3 Months

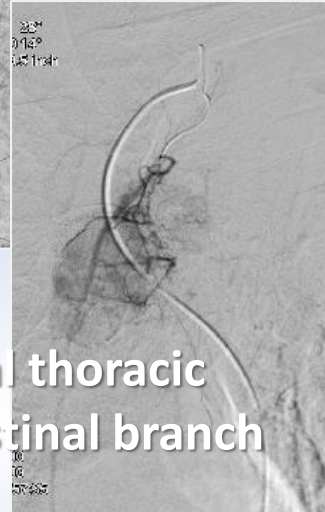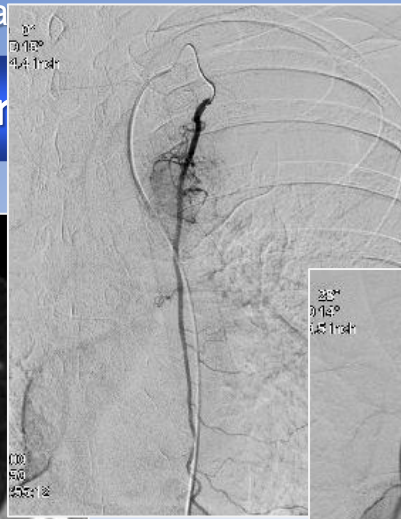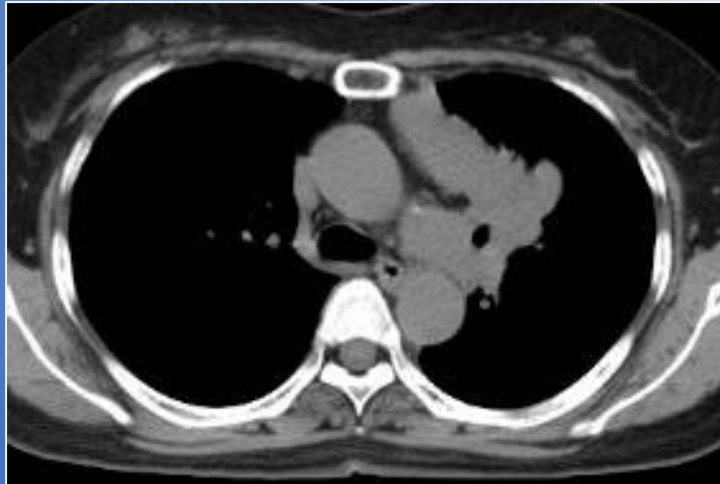
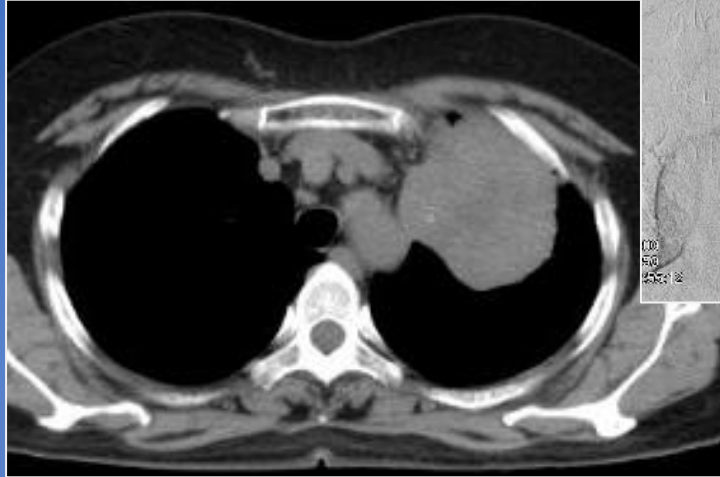
- 7 Months TX

- 1 Month TX

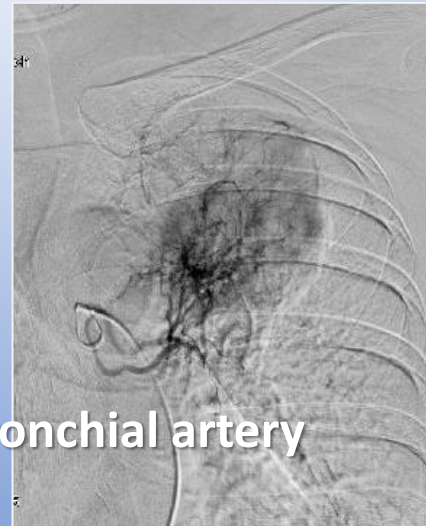TX



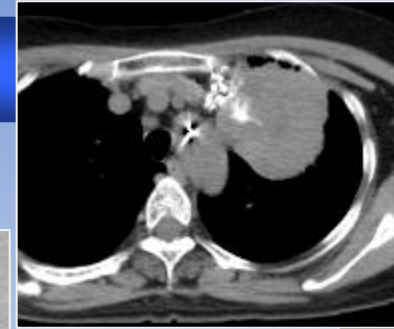
Non-Small Cell Lung Cancer (NSCLC)



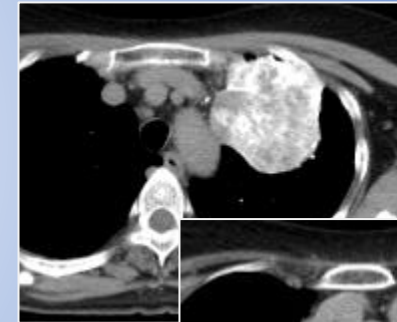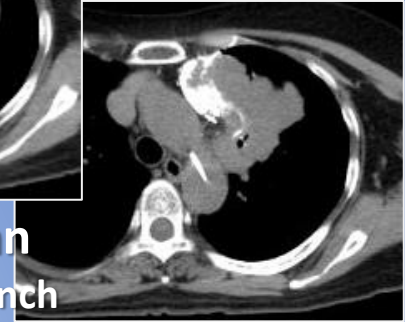Internal thoracic
mediastinal branch



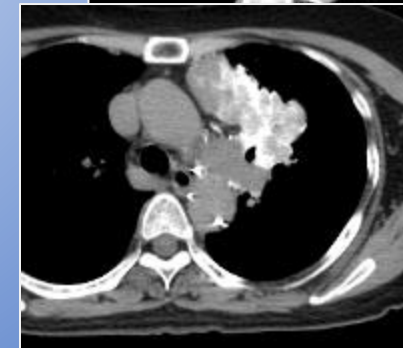
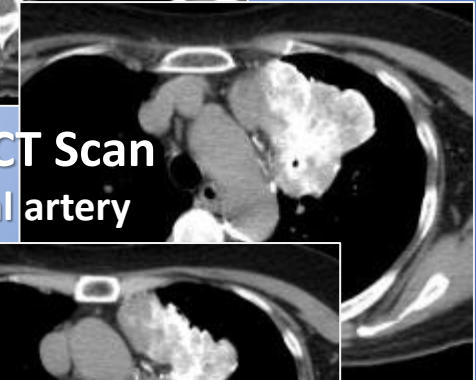
Bronchial artery



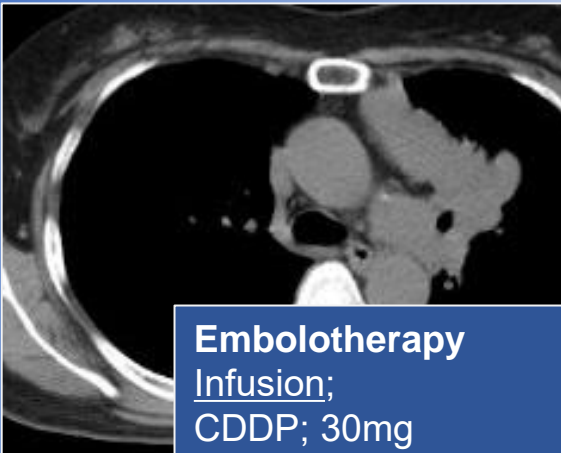
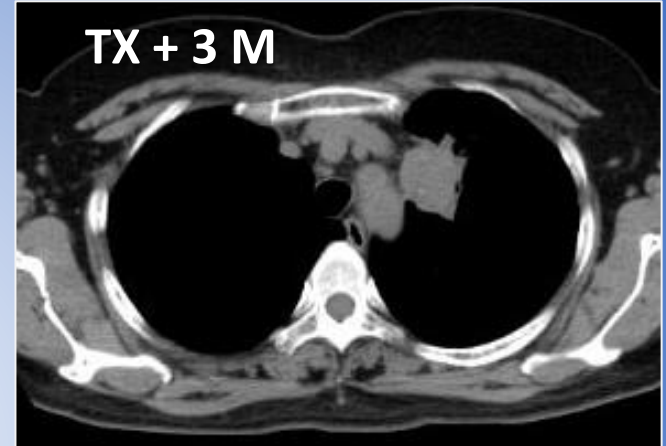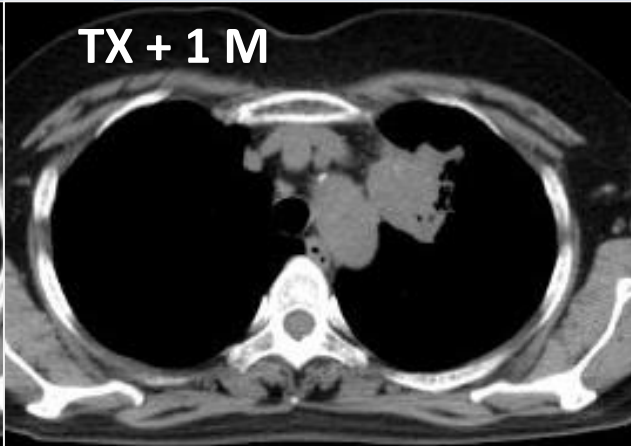
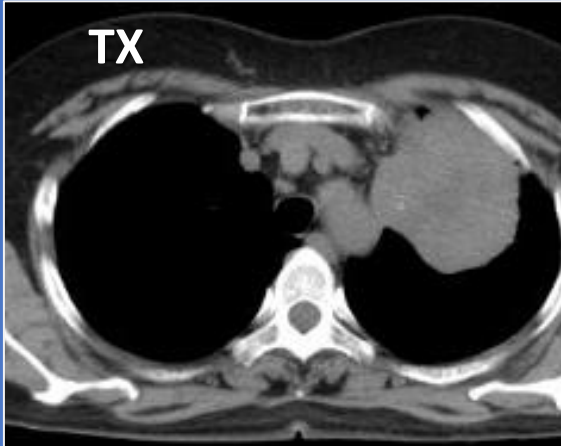
Angio CT Scan
mediastinal branch



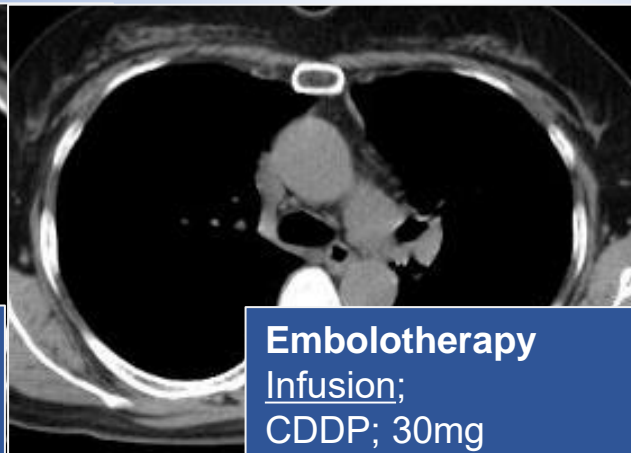
Angio CT Scan
Bronchial artery



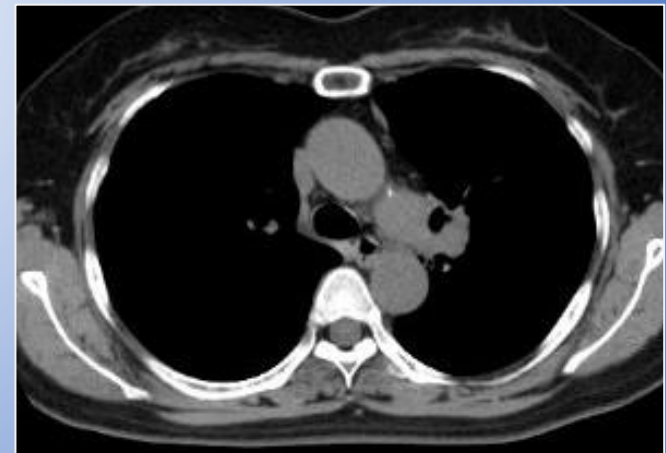
Non-Small Cell Lung Cancer (adenocarcinoma) 70 y/o female



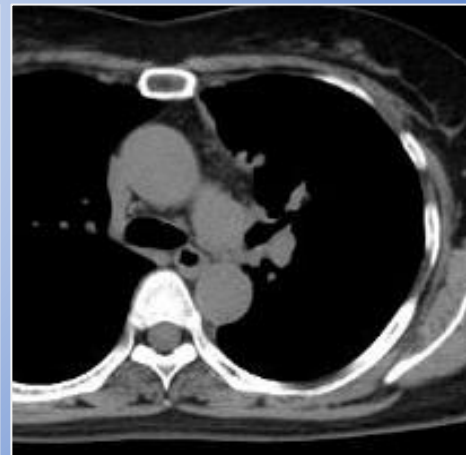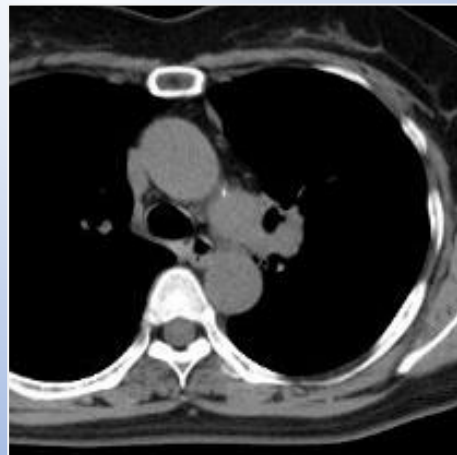
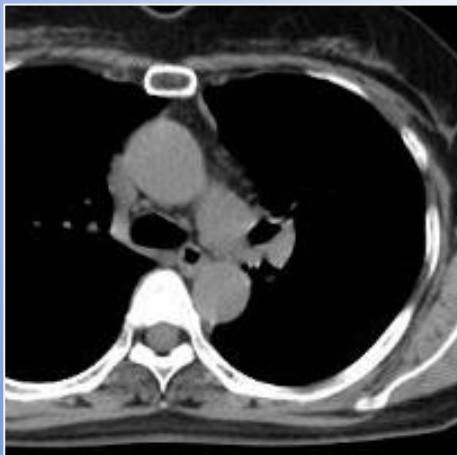
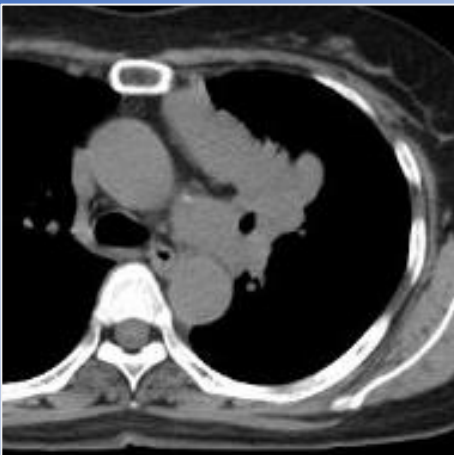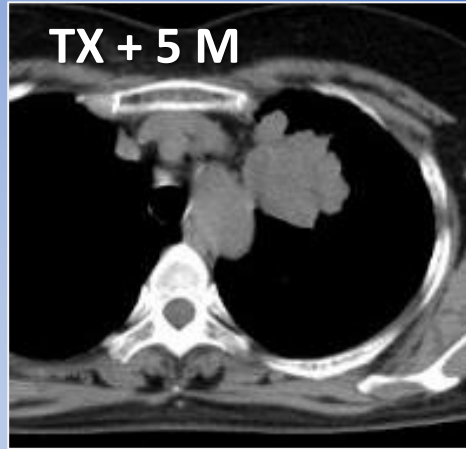
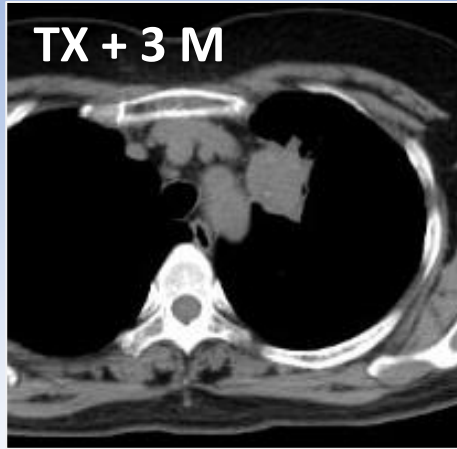
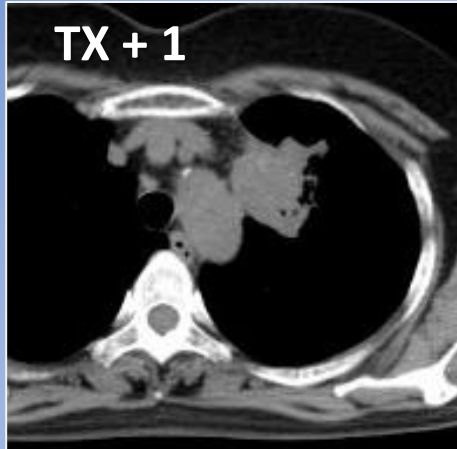
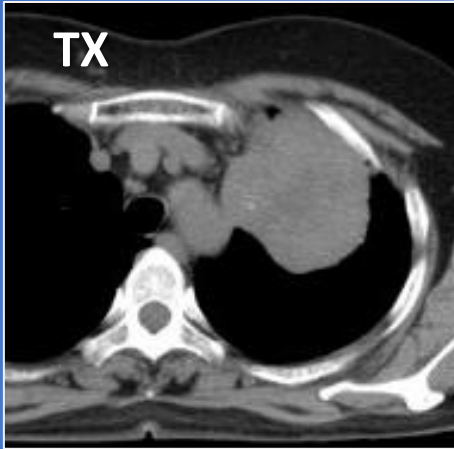
Embolotherapy
Infusion;
CDDP; 30mg
DOC; 20mg
Bevacizumab; 100mg
Embolization
5FU-HS; 0.5mg



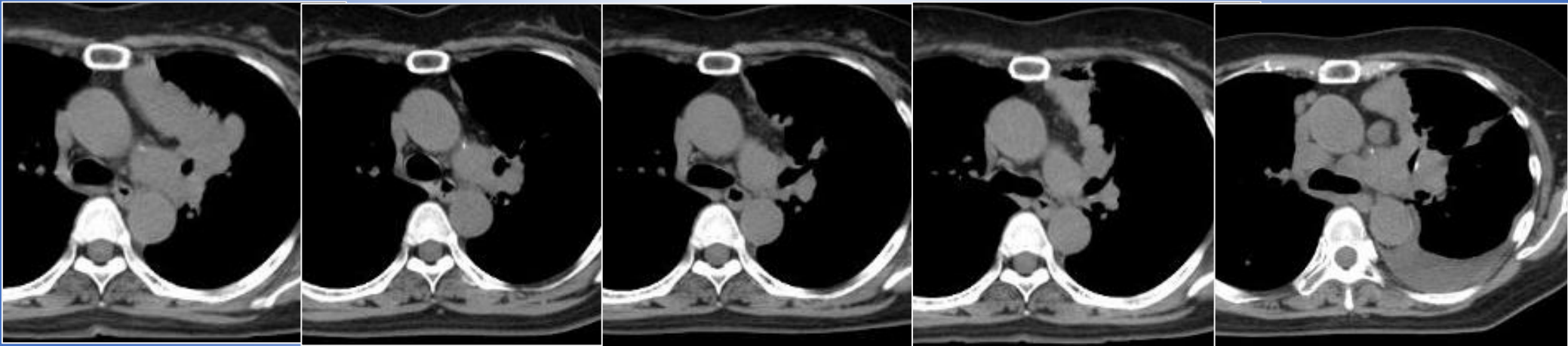
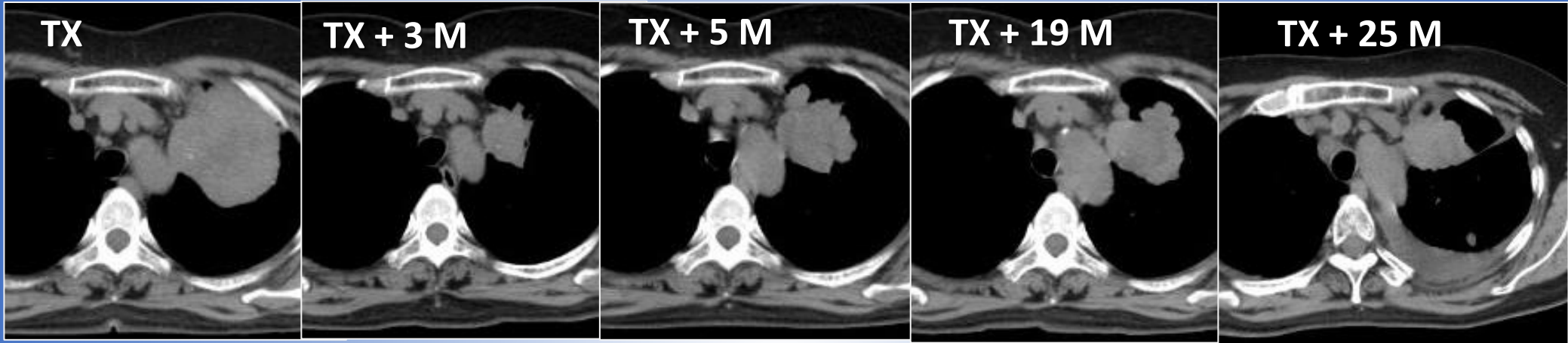
Embolotherapy
Infusion;
CDDP; 30mg
DOC; 20mg
Bevacizumab; 100mg
Embolization
5FU-HS; 0.125mg



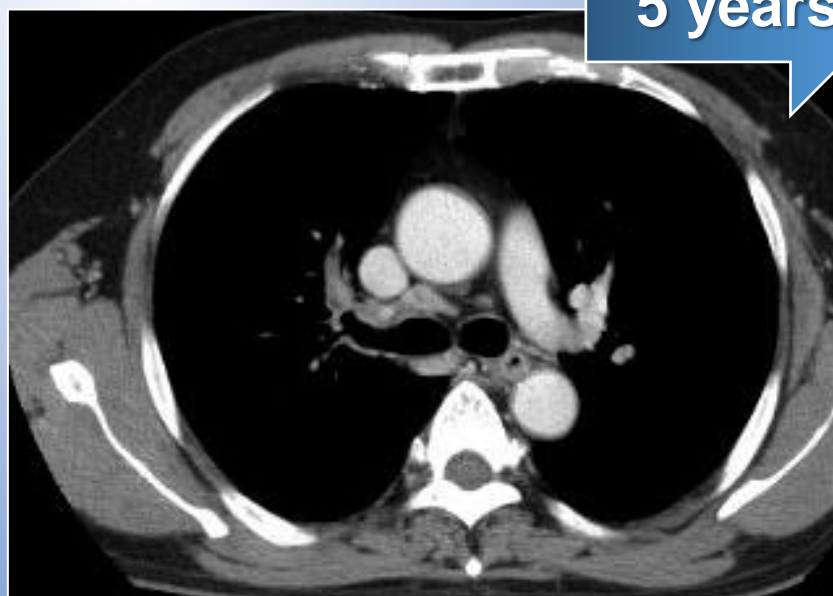
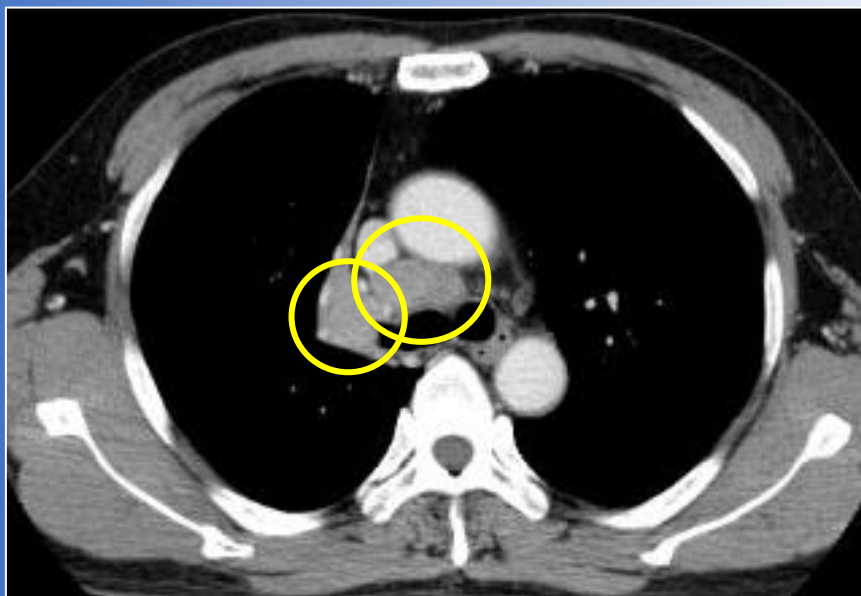
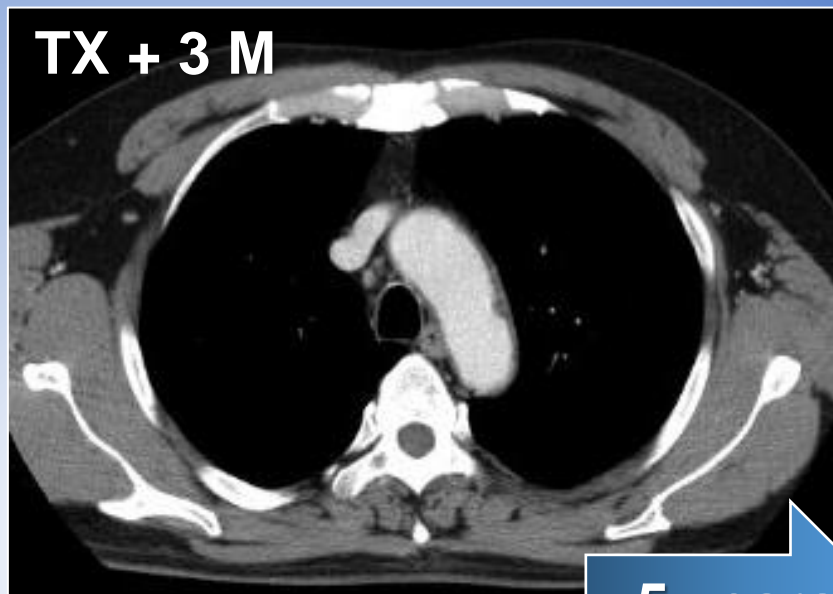
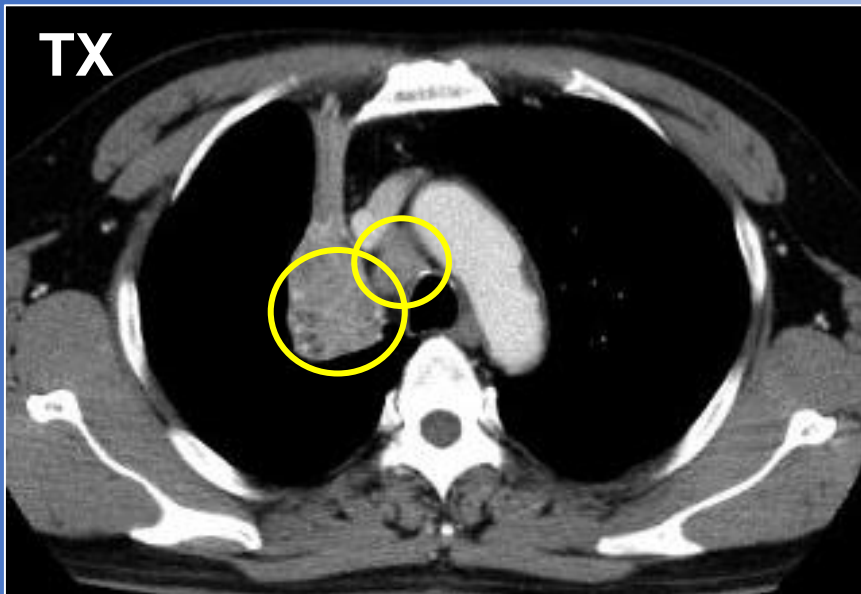
Non-Small Cell Lung Cancer (adenocarcinoma) 70 y/o female



Non-Small Cell Lung Cancer (Adenocarcinoma) 70 y/o female



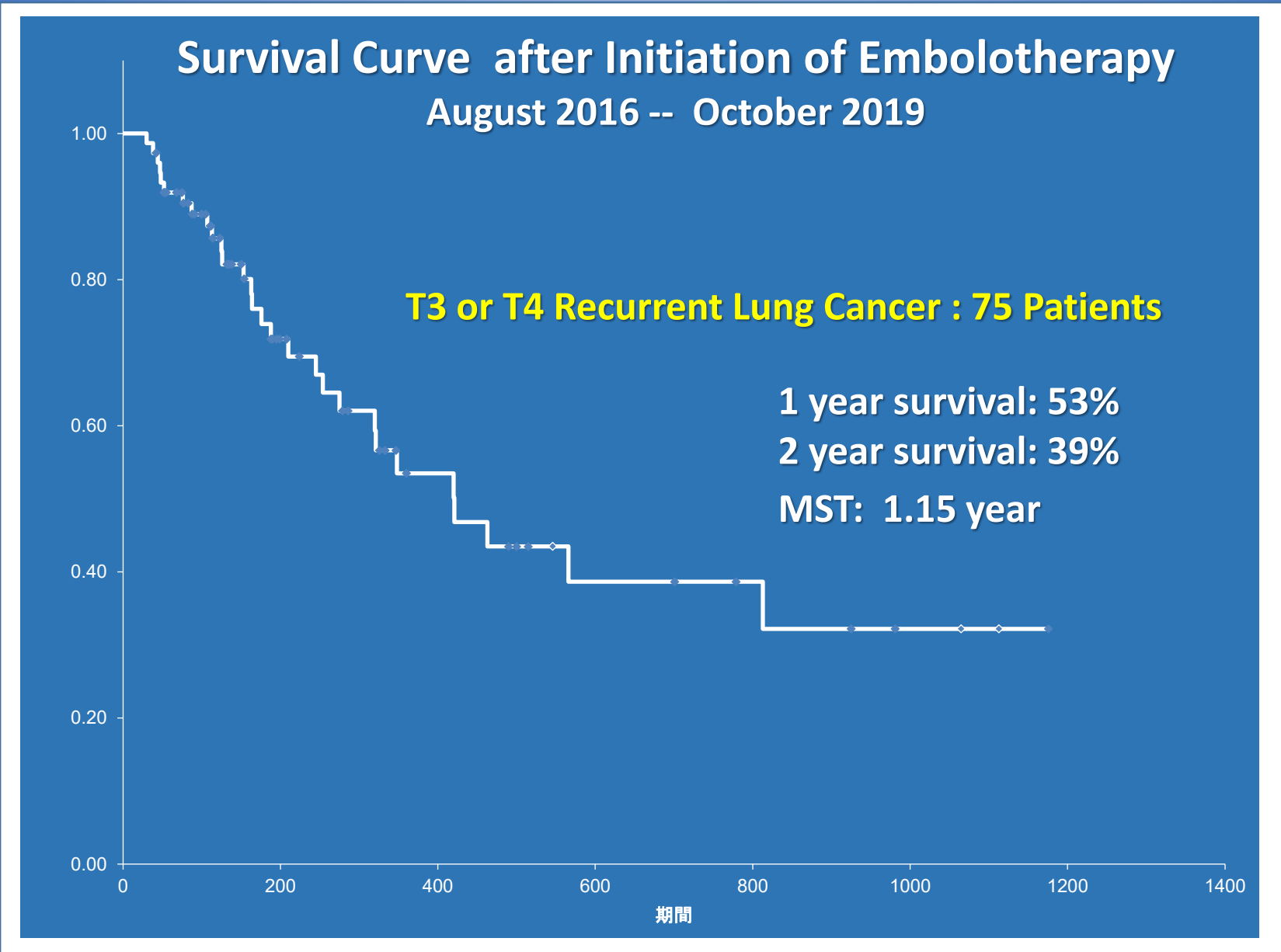
Primary lung cancer with mediastinal lymph node metastases 56 y/o



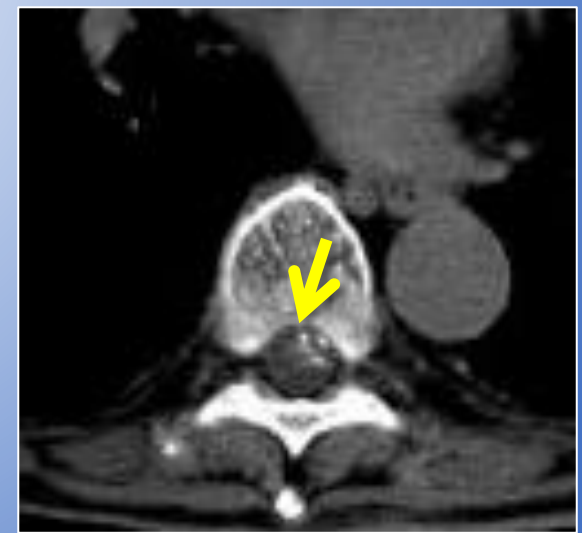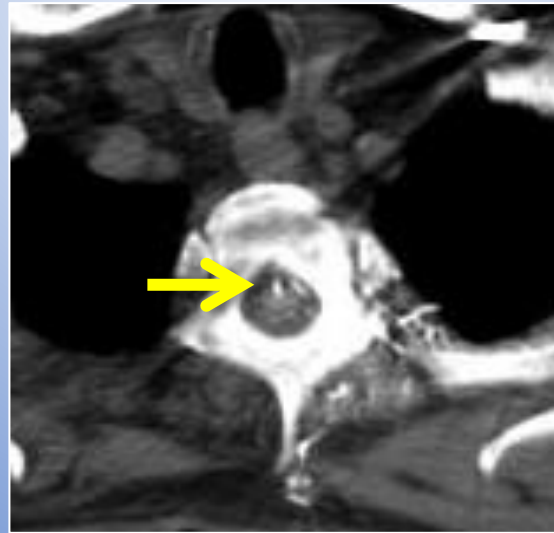
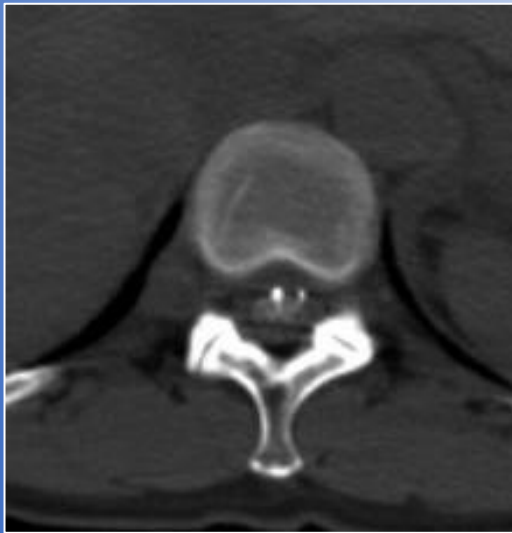
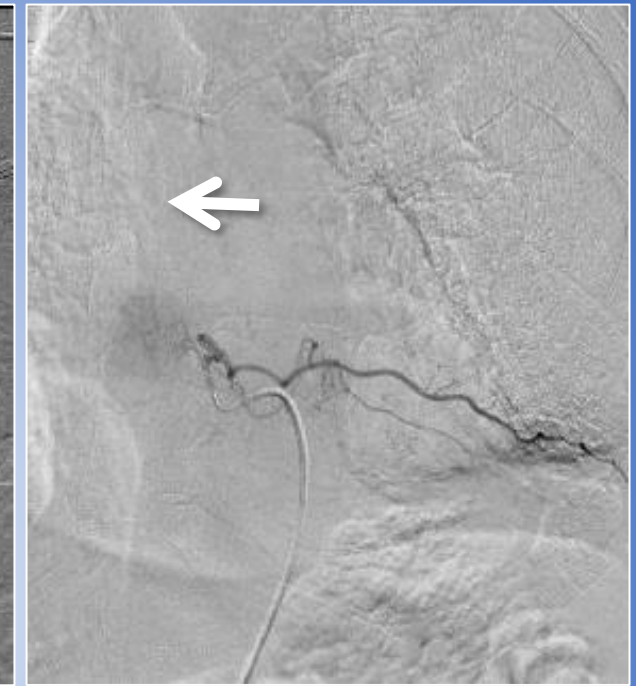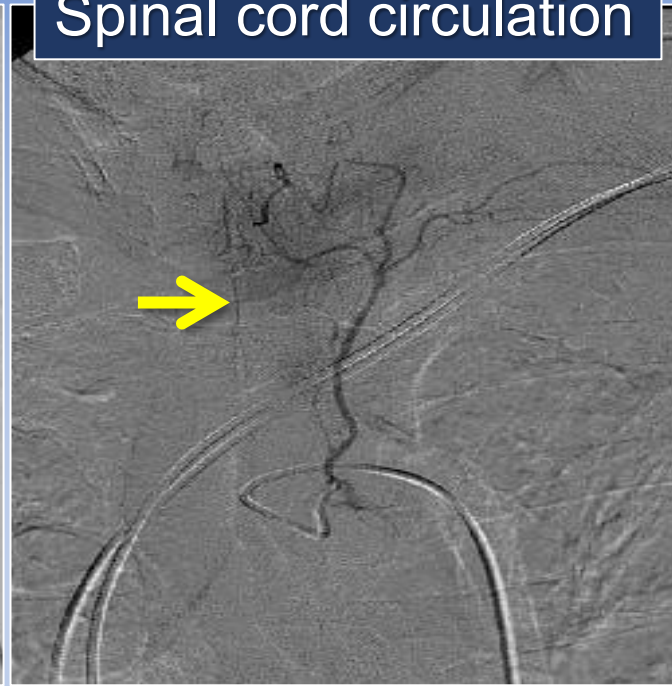
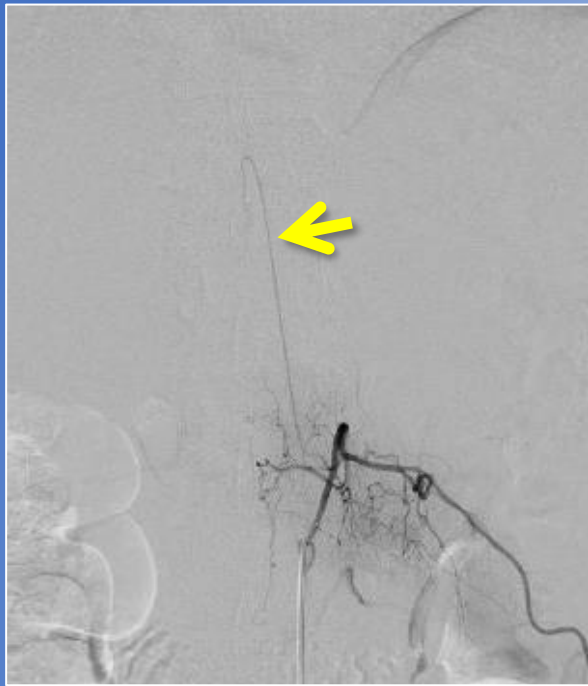5 years

2019.11.22

No sign of recurrence



Spinal cord circulation



Take Home Message from IGT Clinic

Transarterial treatments for lung and mediastinal tumors

- Technologies in TACE have been improved in these two decades.
- A microcatheter is safely advanced into lesions in lung tumors.
- Microspheres are safe embolic materials for lung tumors.
- Primary lung cancers invading pulmonary hilum or mediastinum can effectively be treated by m-TACE.
- Repetition of treatment in a rather short term is indispensable.
- Prevention of spinal injury should always be considered.
- Transarterial treatment has a great potential as a minimum invasive loco-regional therapy to improve prognosis with less adverse events.

Thank you